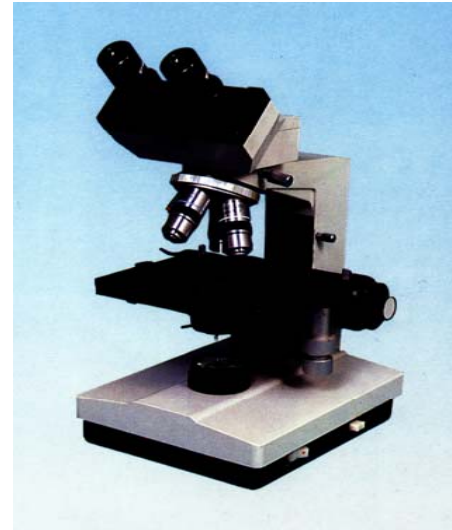
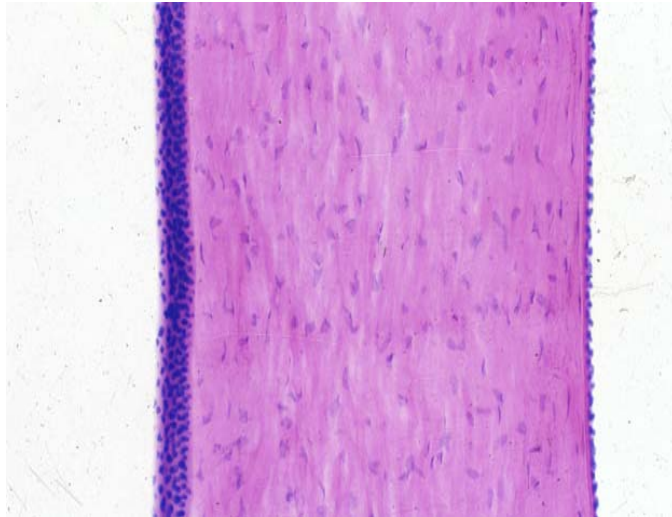



Experimental Courseware of Histology and Embryology



Chapter 1 Introduction and Cell

Chapter 2 Epithelial tissue

Chapter 3 Connective Tissue

Chapter 4 Blood

Chapter 5 Cartilage and Bone

Chapter 6 Muscle Tissue

Chapter 7 Nerve Tissue

Chapter 8 Circulatory System

Chapter 9 Immune System

Chapter 10 Skin

Chapter 11 Digestive Tract

Chapter 12 Digestive Gland

Chapter 13 Respiratory System

Chapter 14 Urinary System

Chapter 15 Endocrine System

[Chapter 16 Sense Organs](#)

Chapter 17 Male Reproduction

Chapter 18 Female Reproduction

Chapter 19 Embryology 1

Chapter 20 Embryology 2

Chapter 16 Organs of Special Sense

I Slides

II Sections

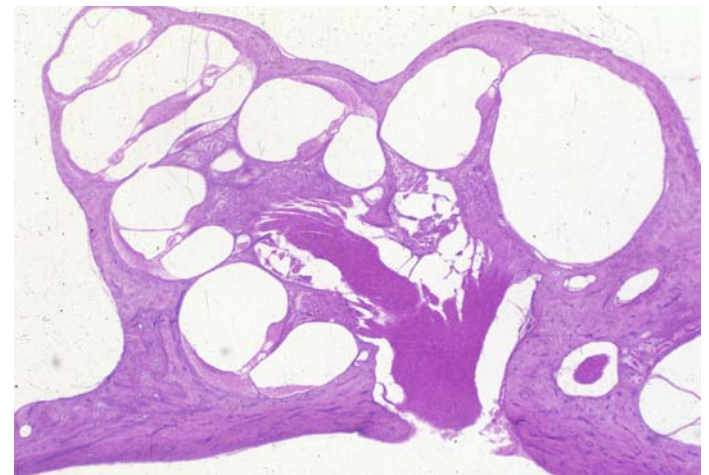
[NO.48 anterior half of the eyeball](#)

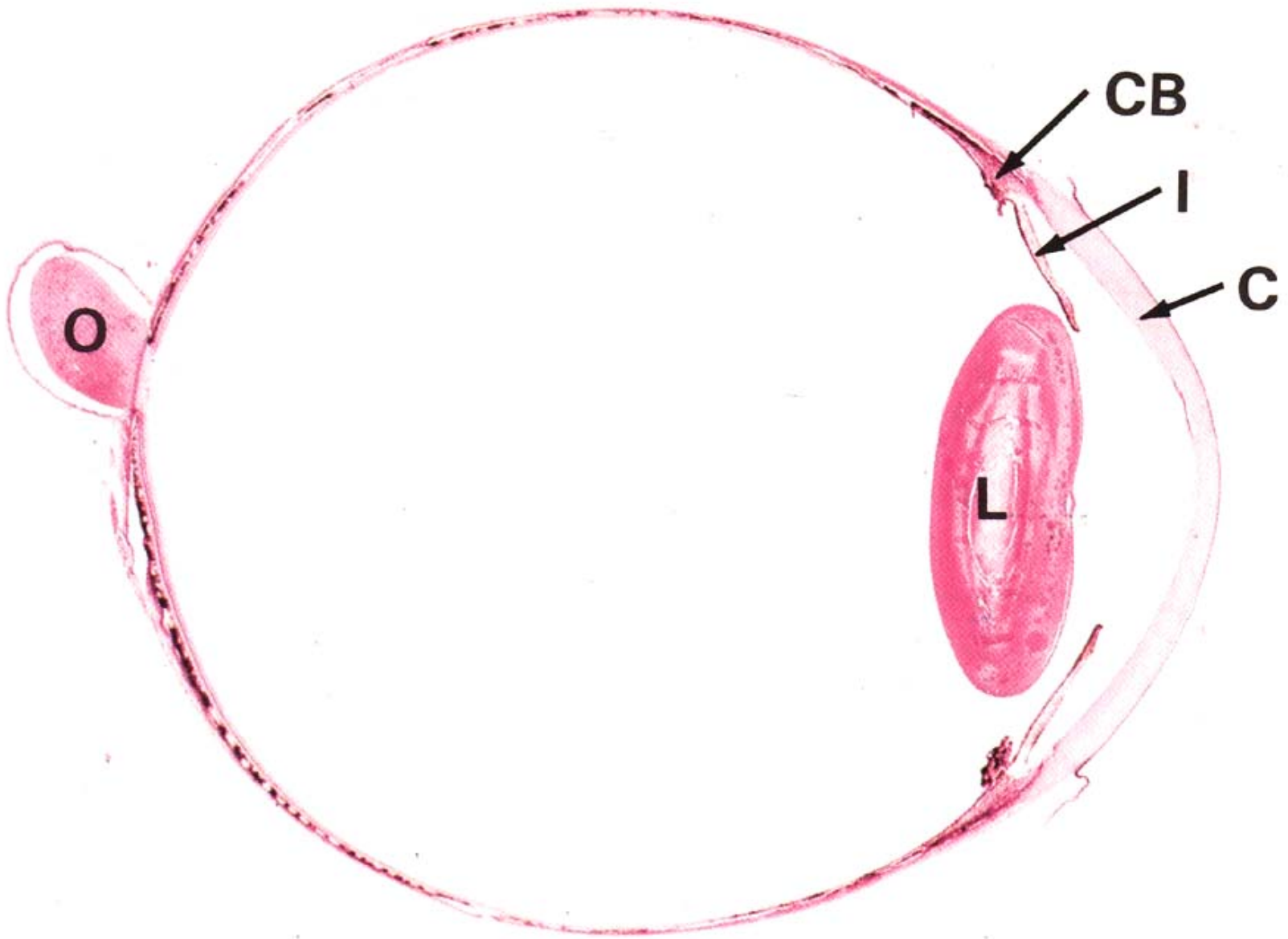
[NO.49 posterior half of the eyeball](#)

[NO.51 inner ear](#)

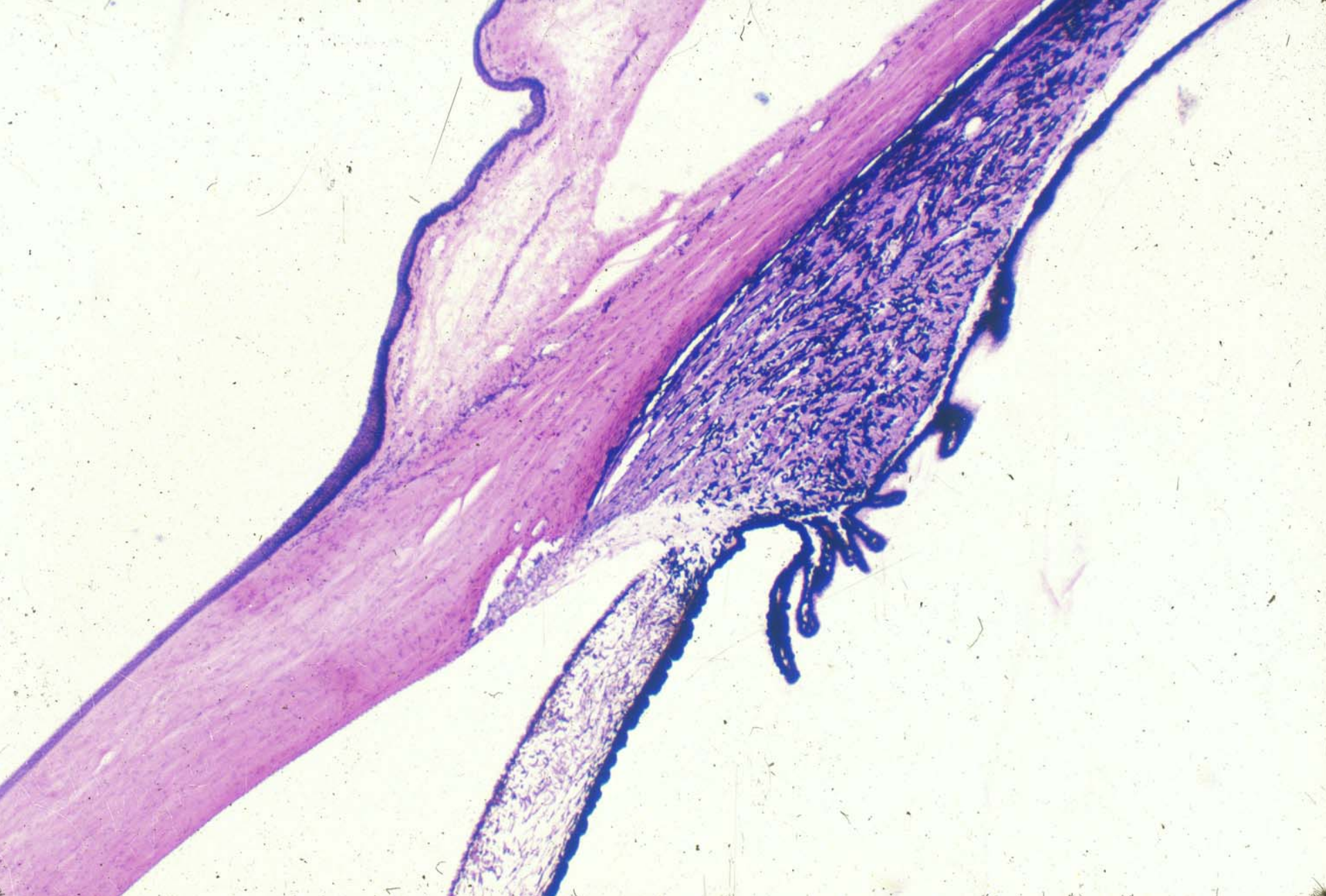III EM photos: 44---47

IV Summary

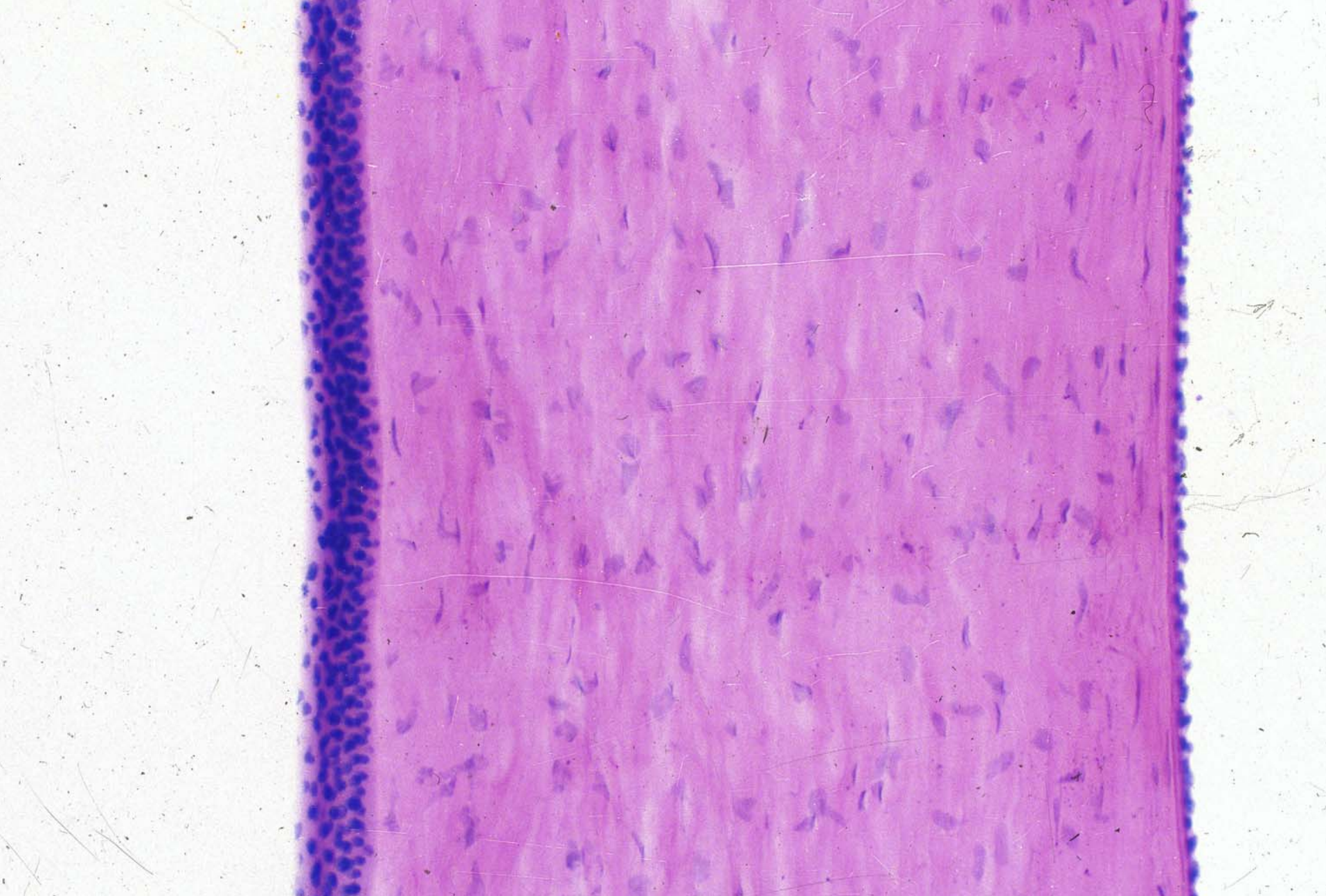





Eyeball



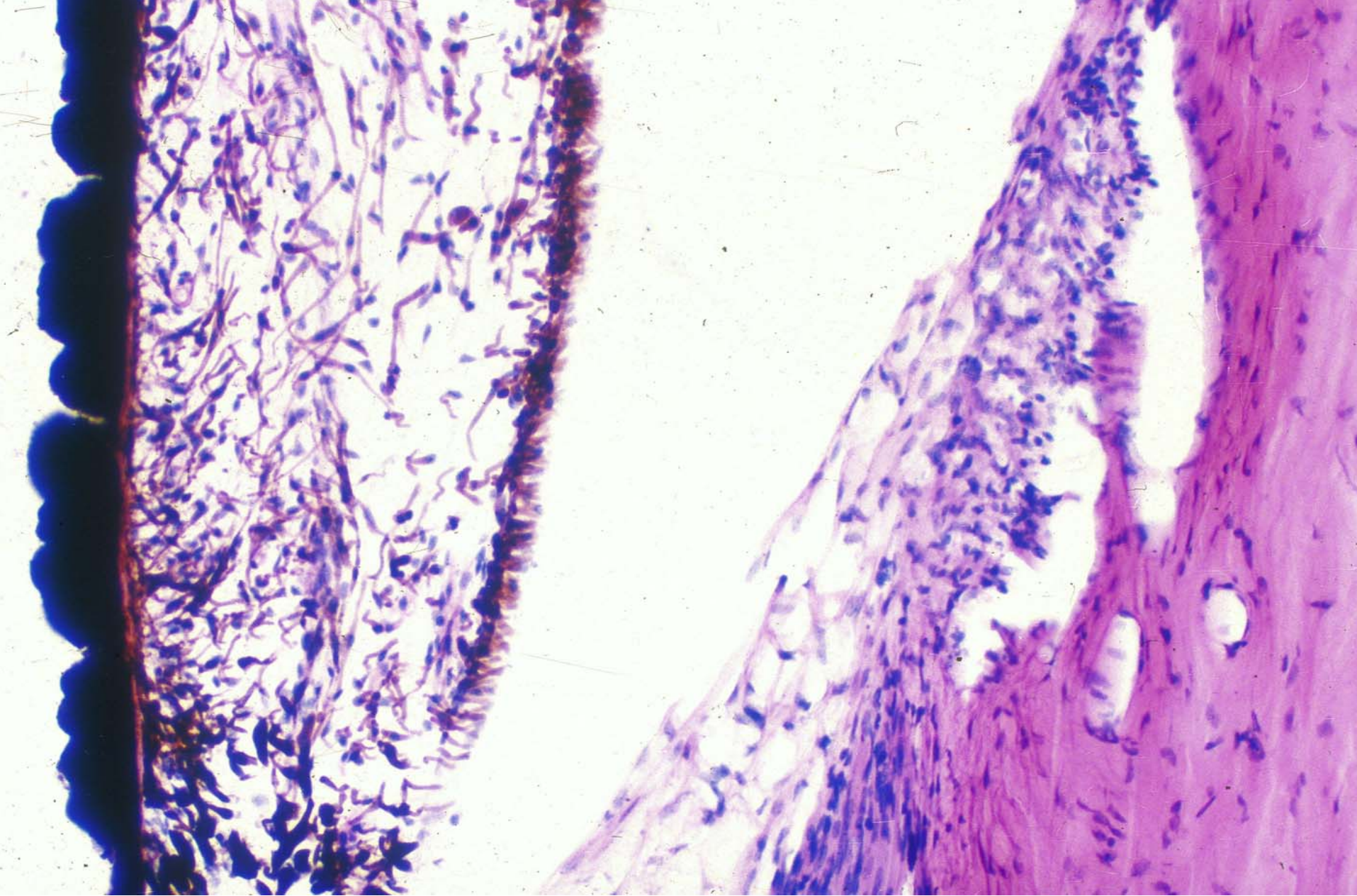
posterior half of the eyeball



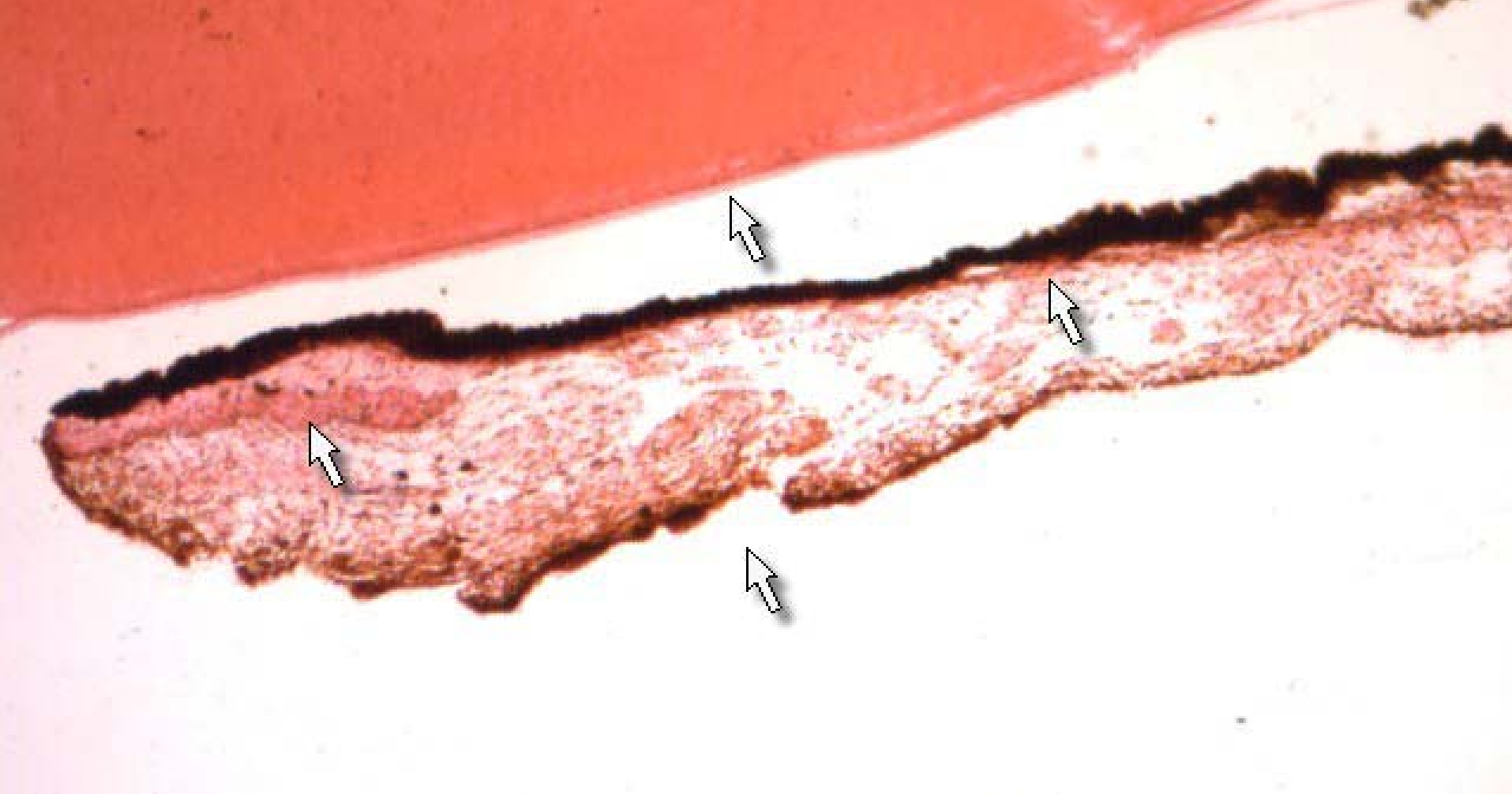
cornea



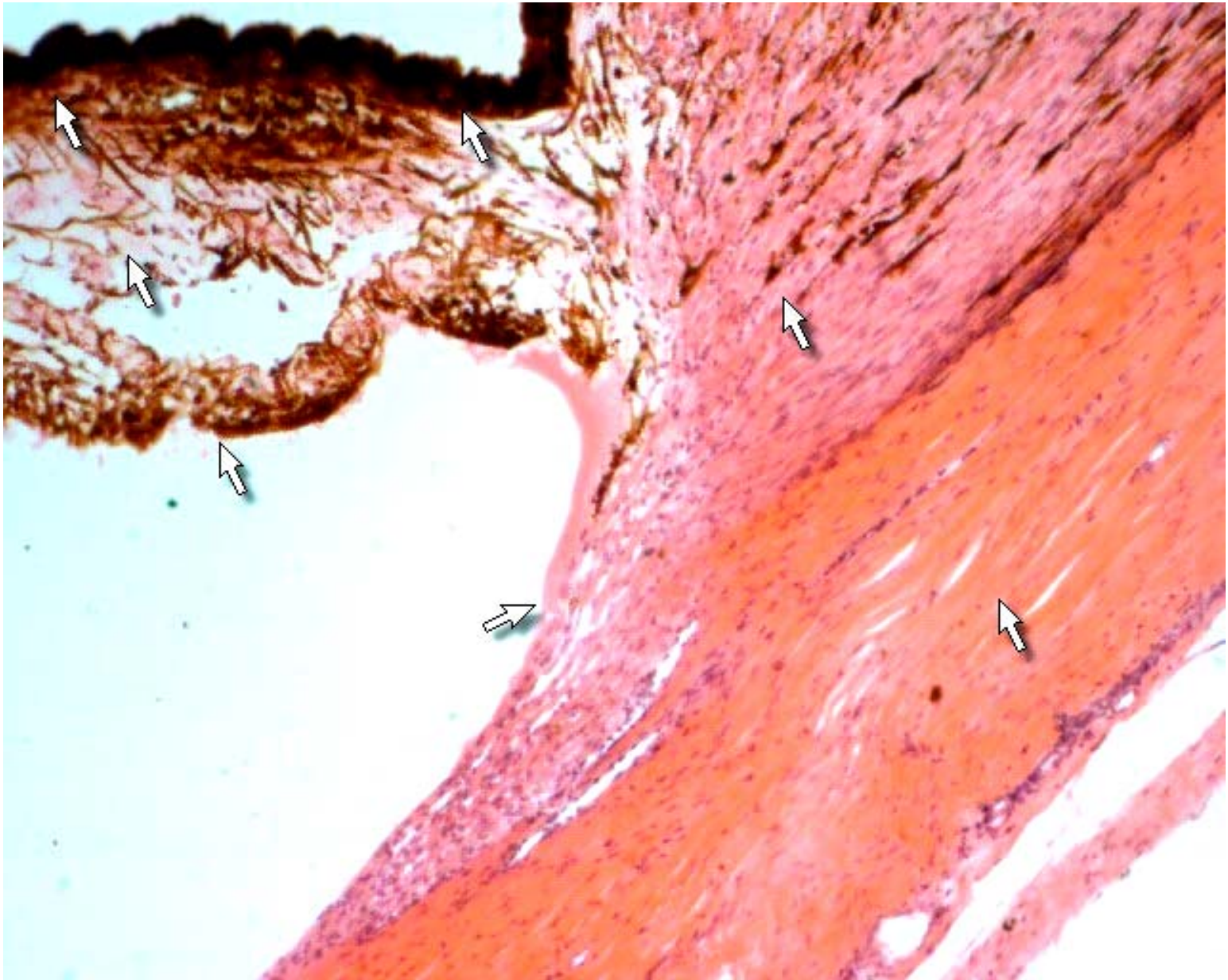
cornea



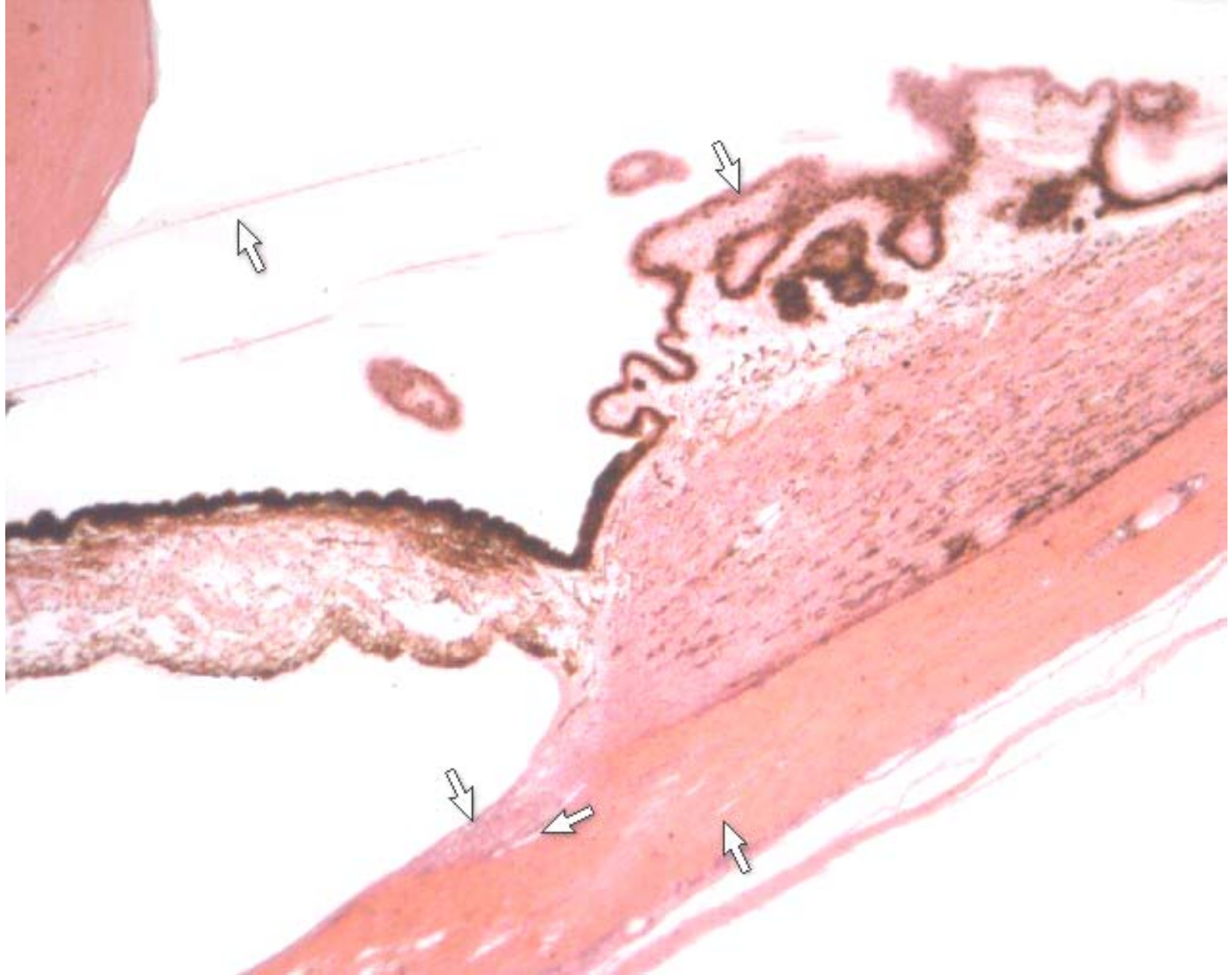
Iris, trabecular meshwork and sinus venosus sclerae



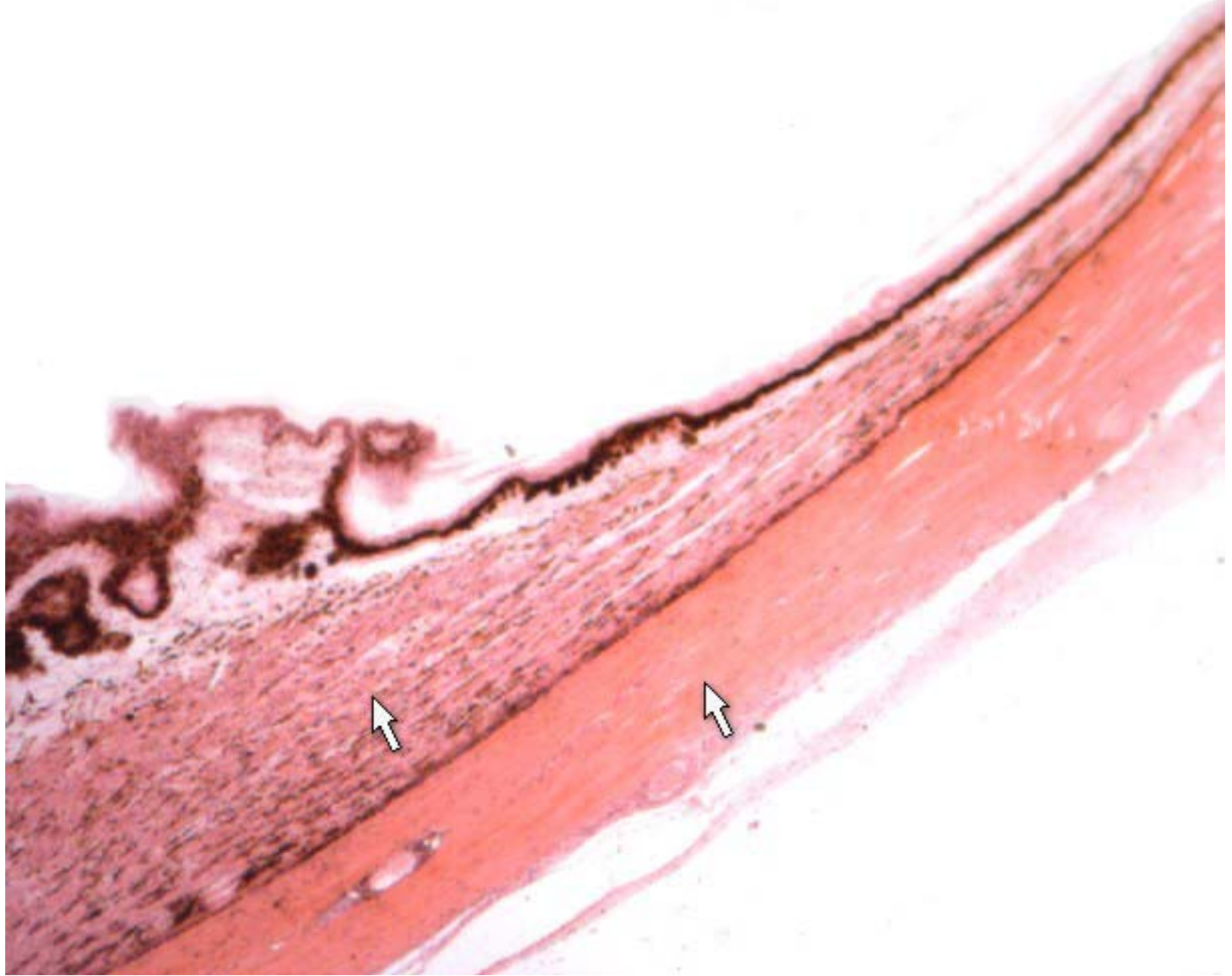
Iris and lens



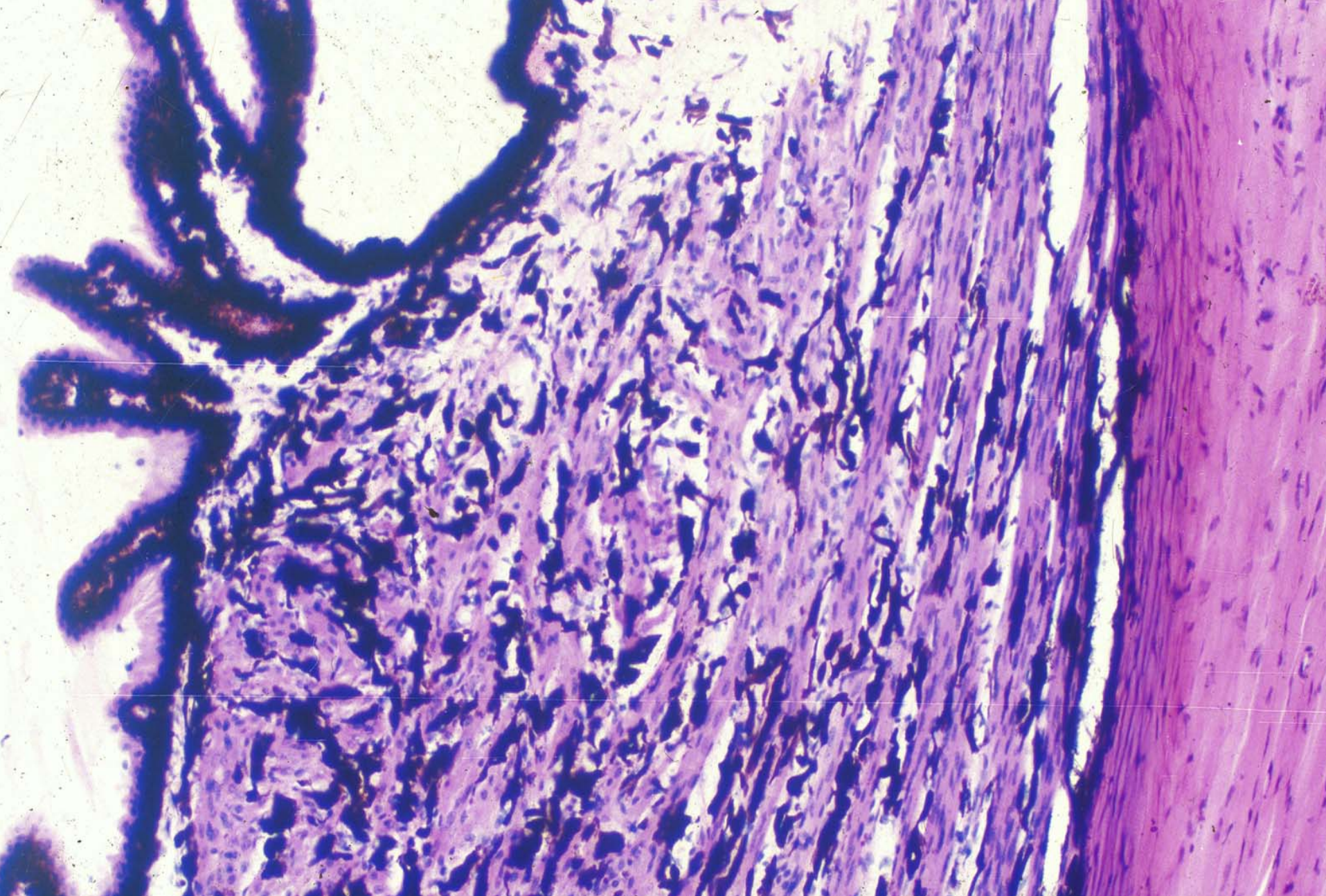
Iris, scleral spur and sclera



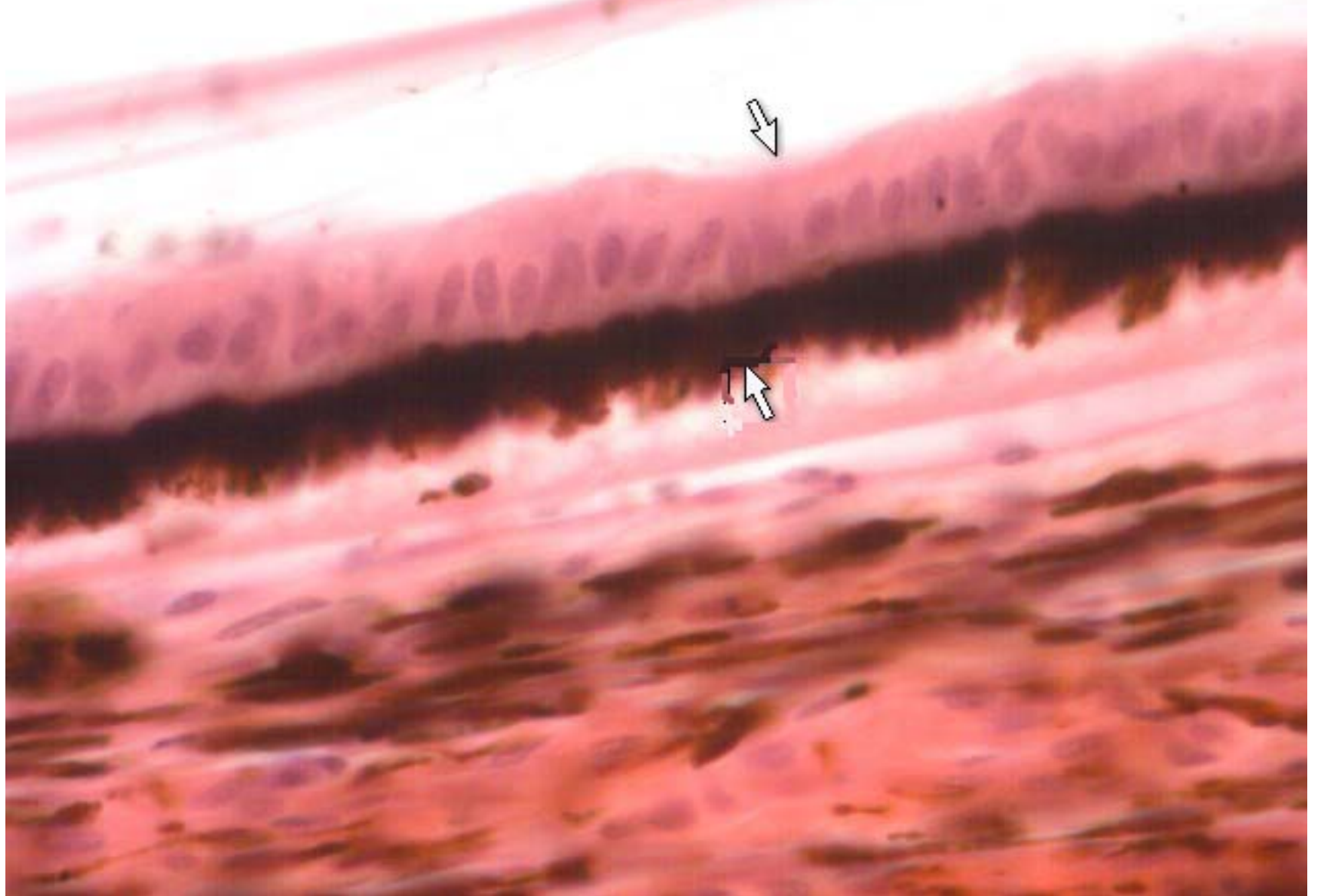
scleral spur, sinus venosus sclerae and ciliary body



ciliary body and sclera



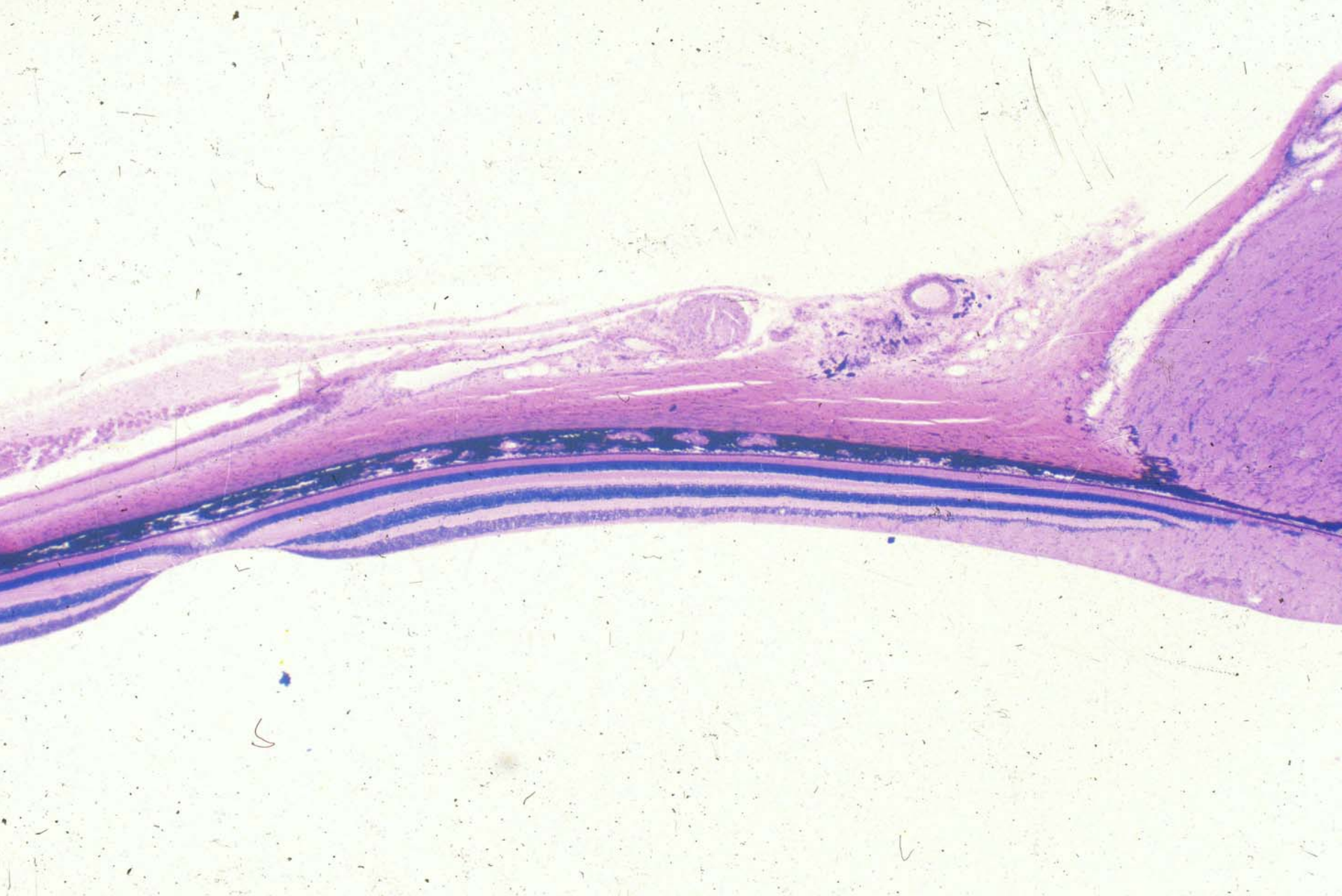ciliary body



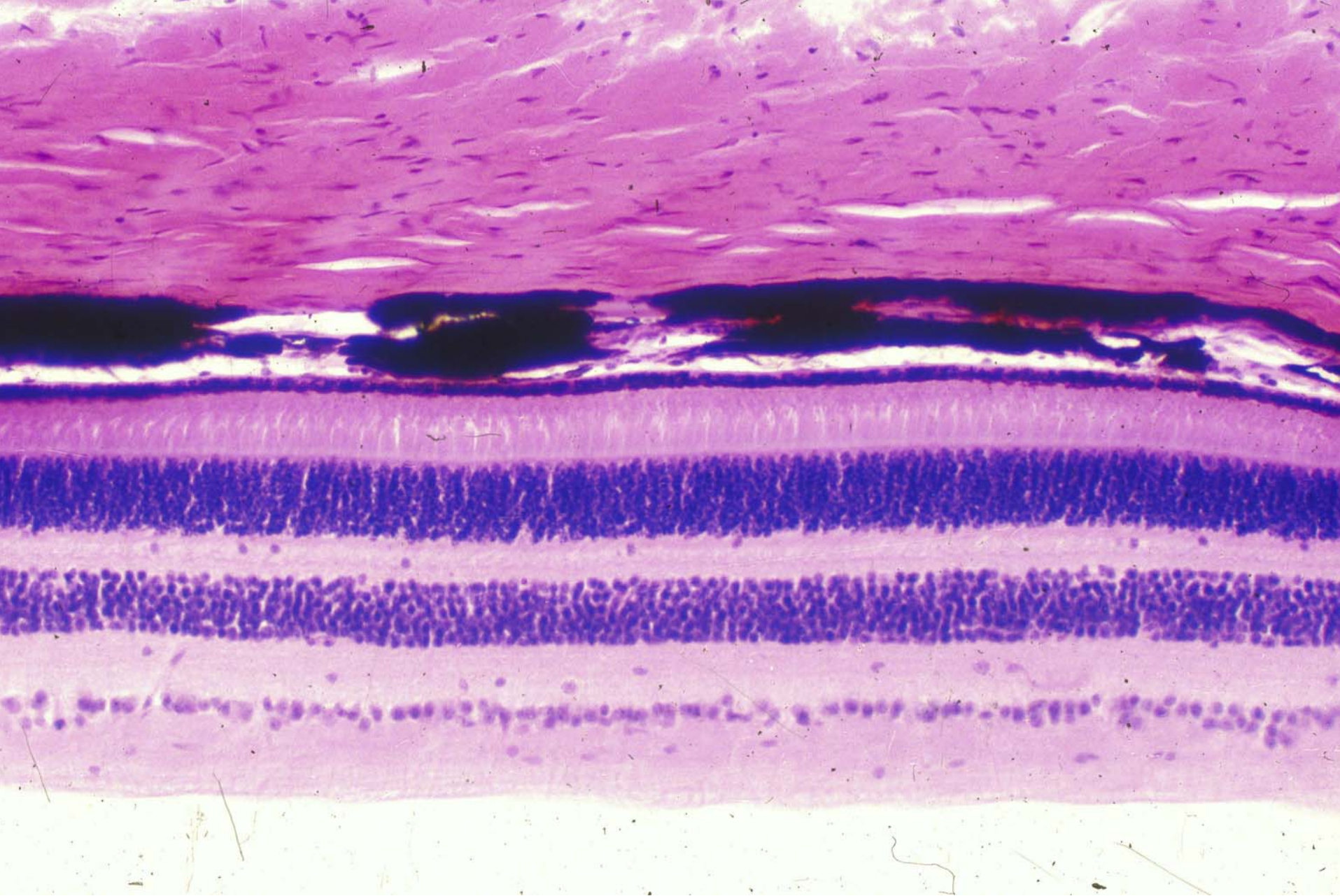
ciliary body



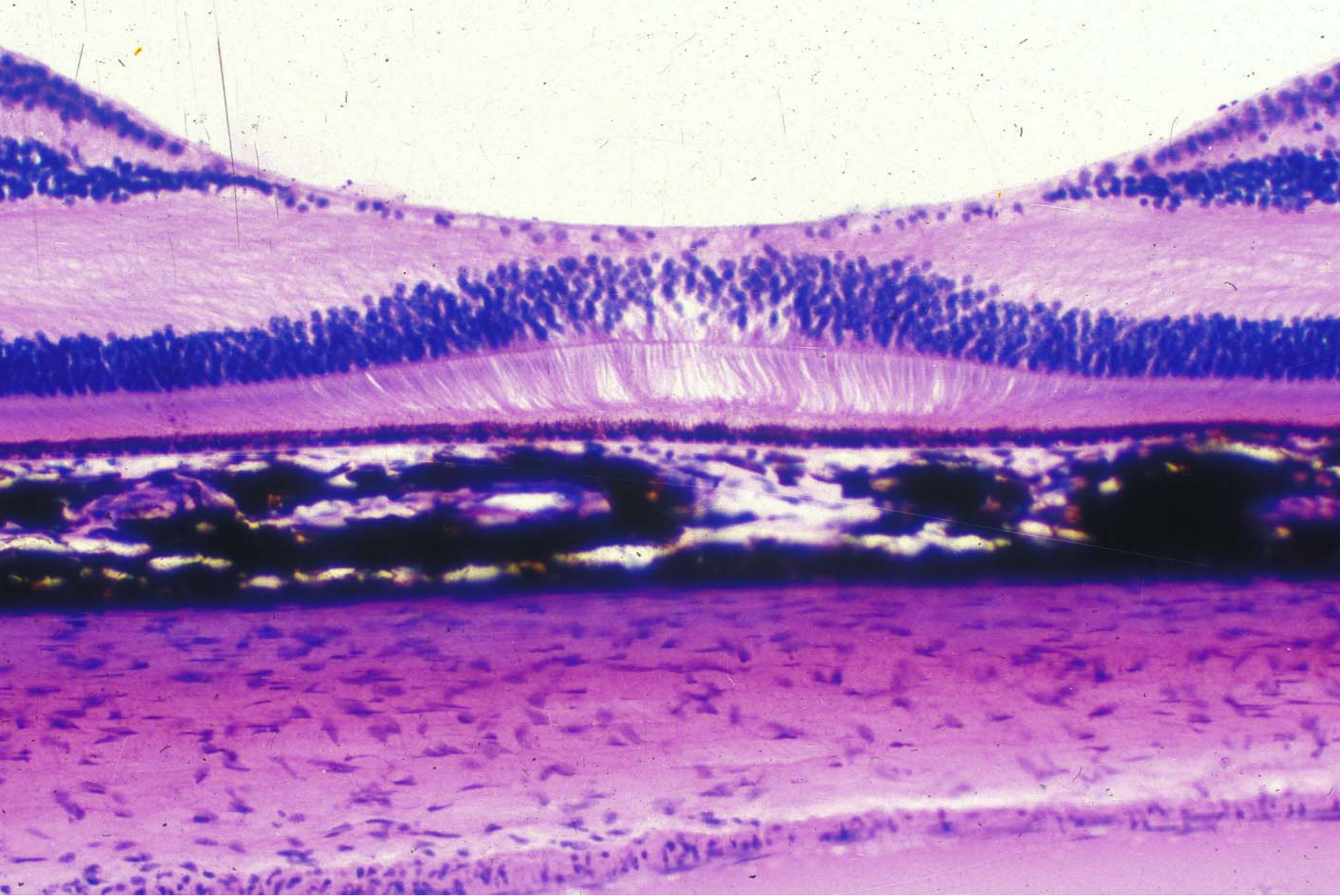
Lens



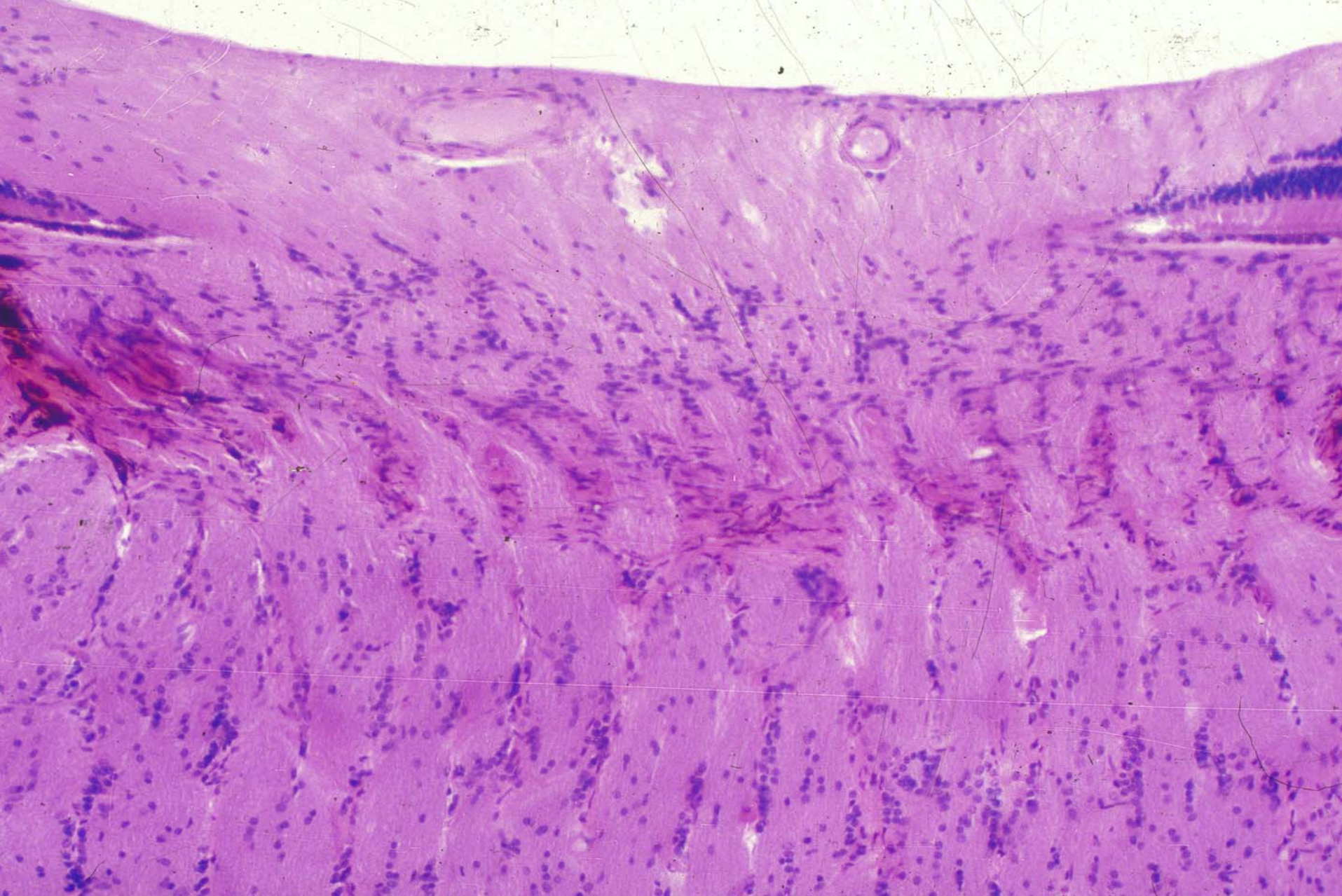
posterior half of the eyeball



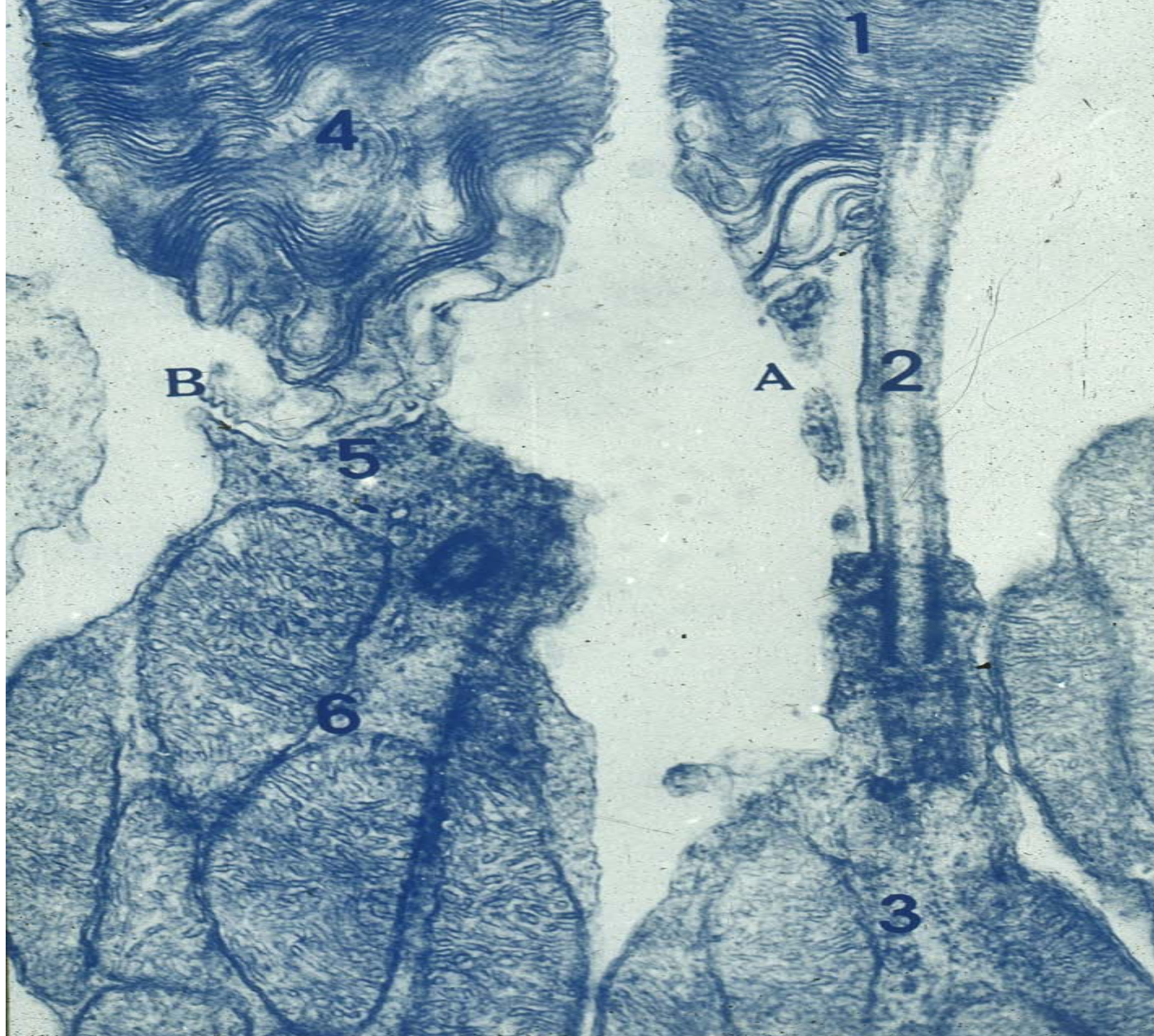
Retina




Central fovea



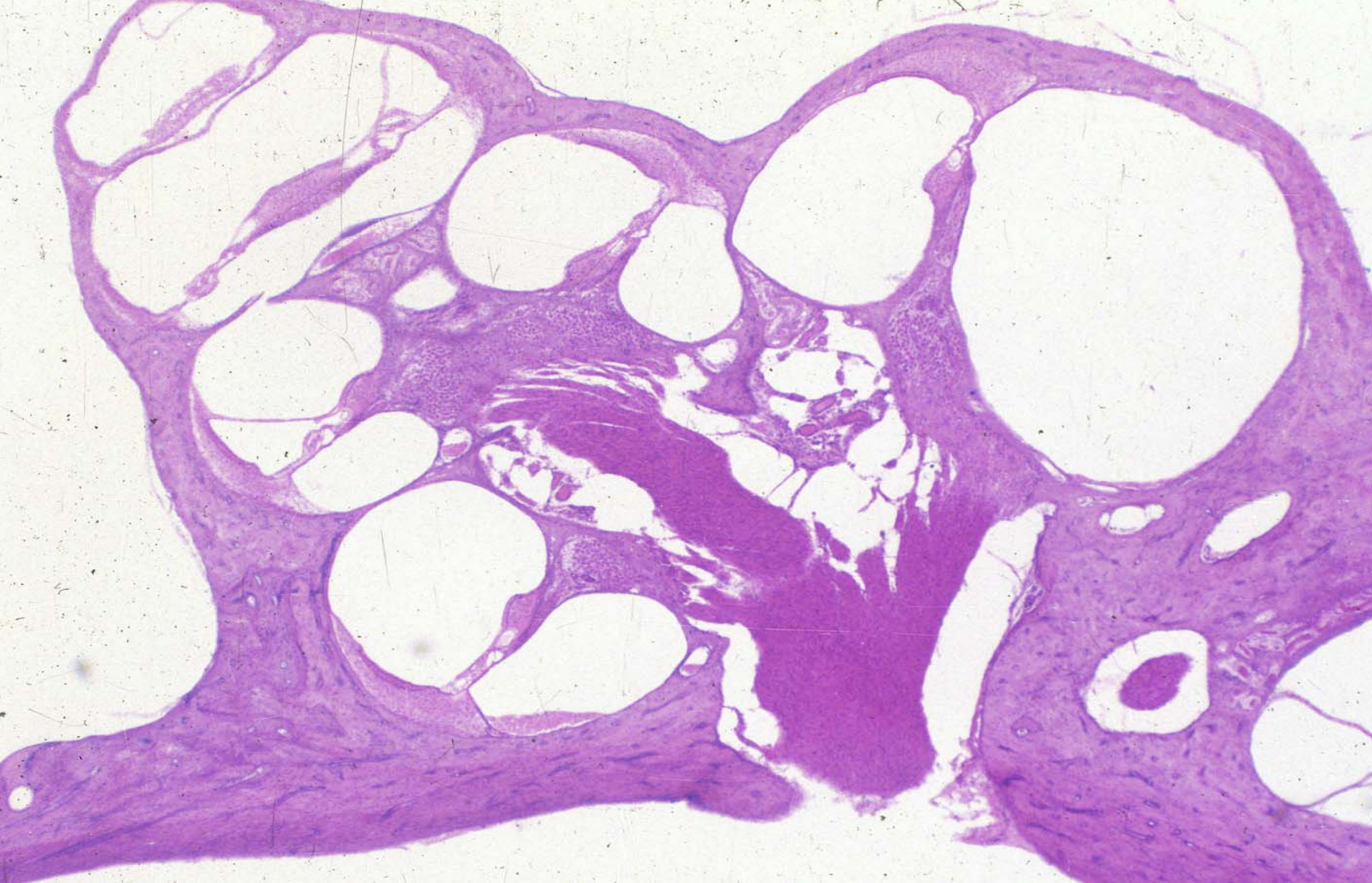
Papilla of optic nerve



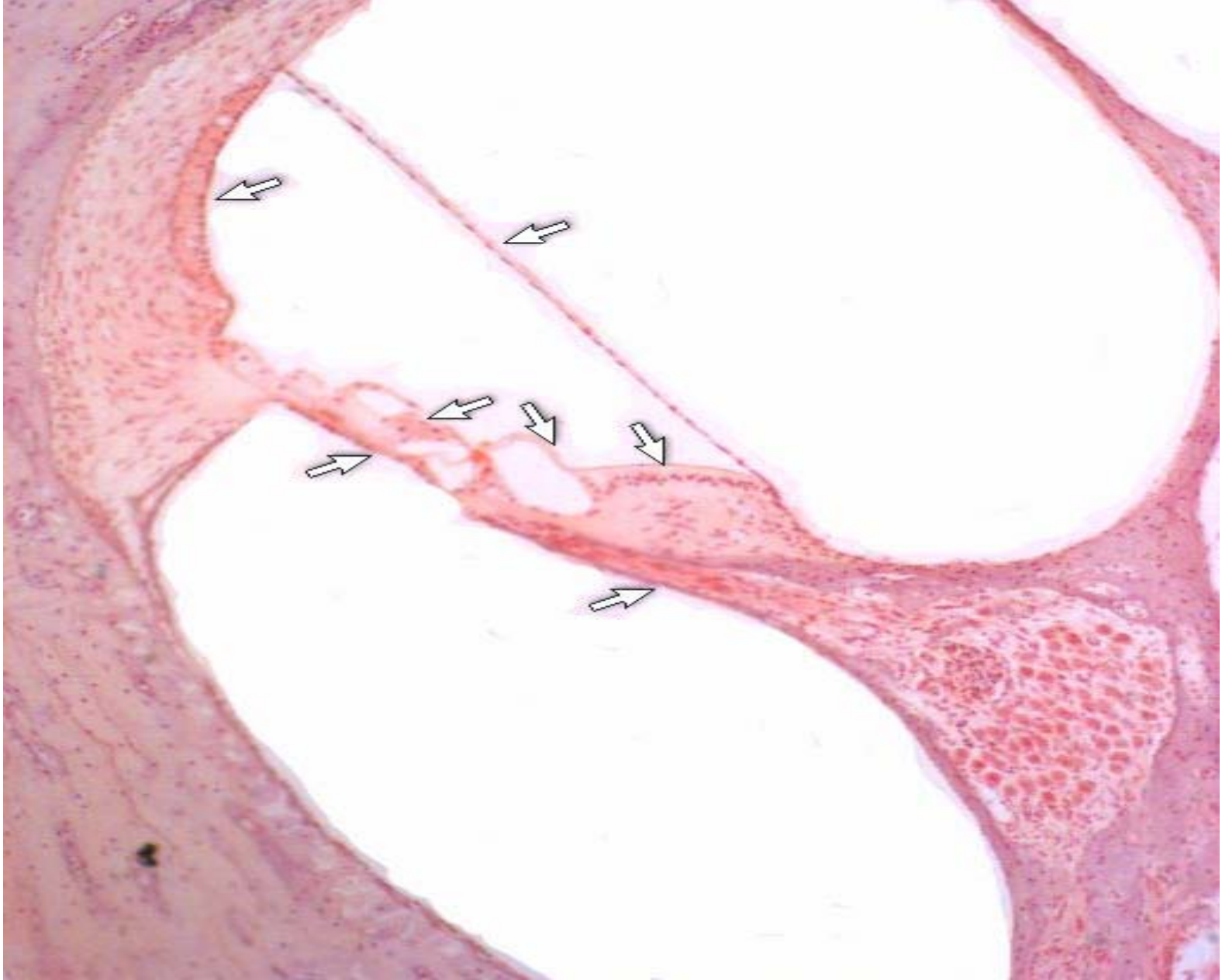Cone cell and rod cell



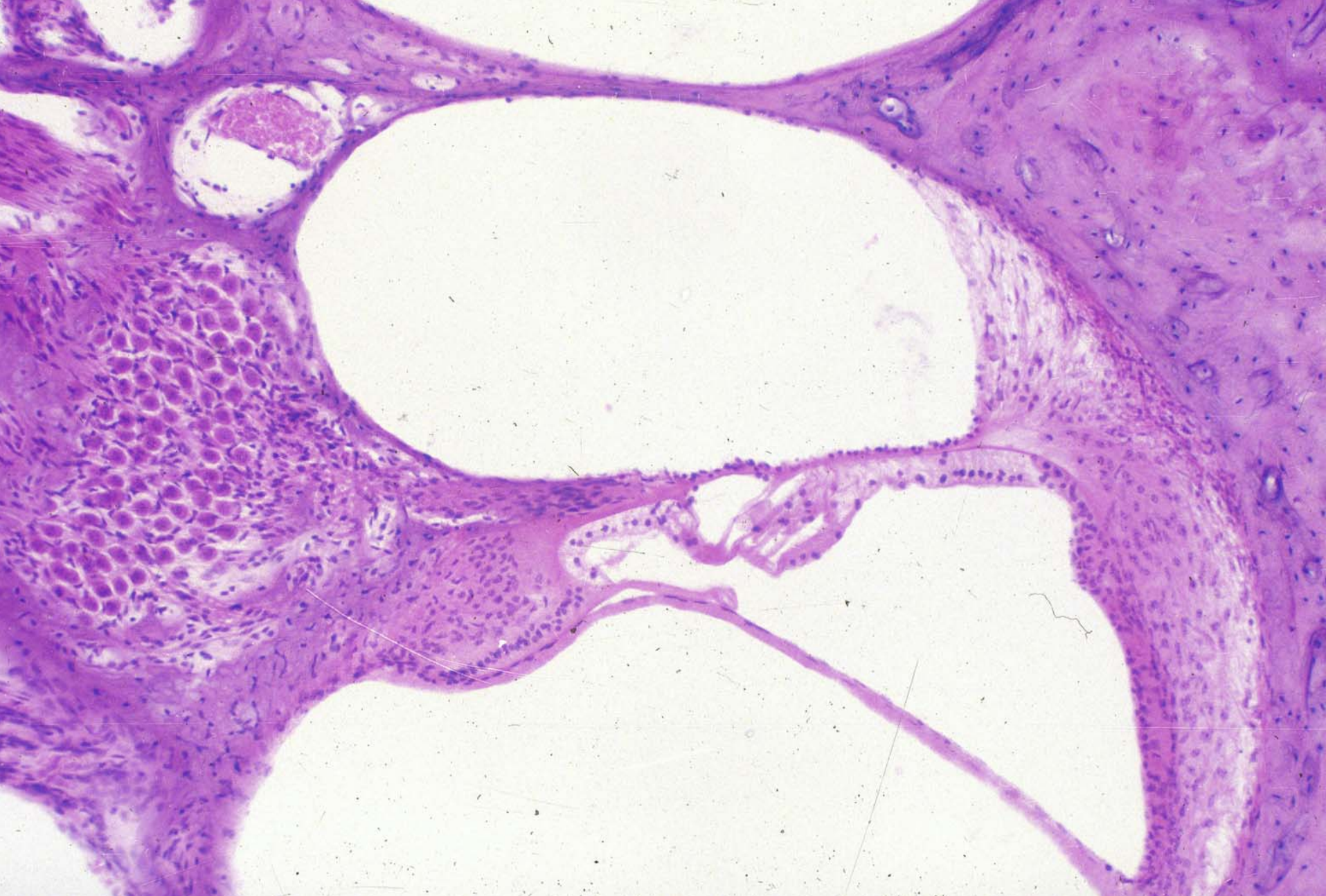
Rod cell



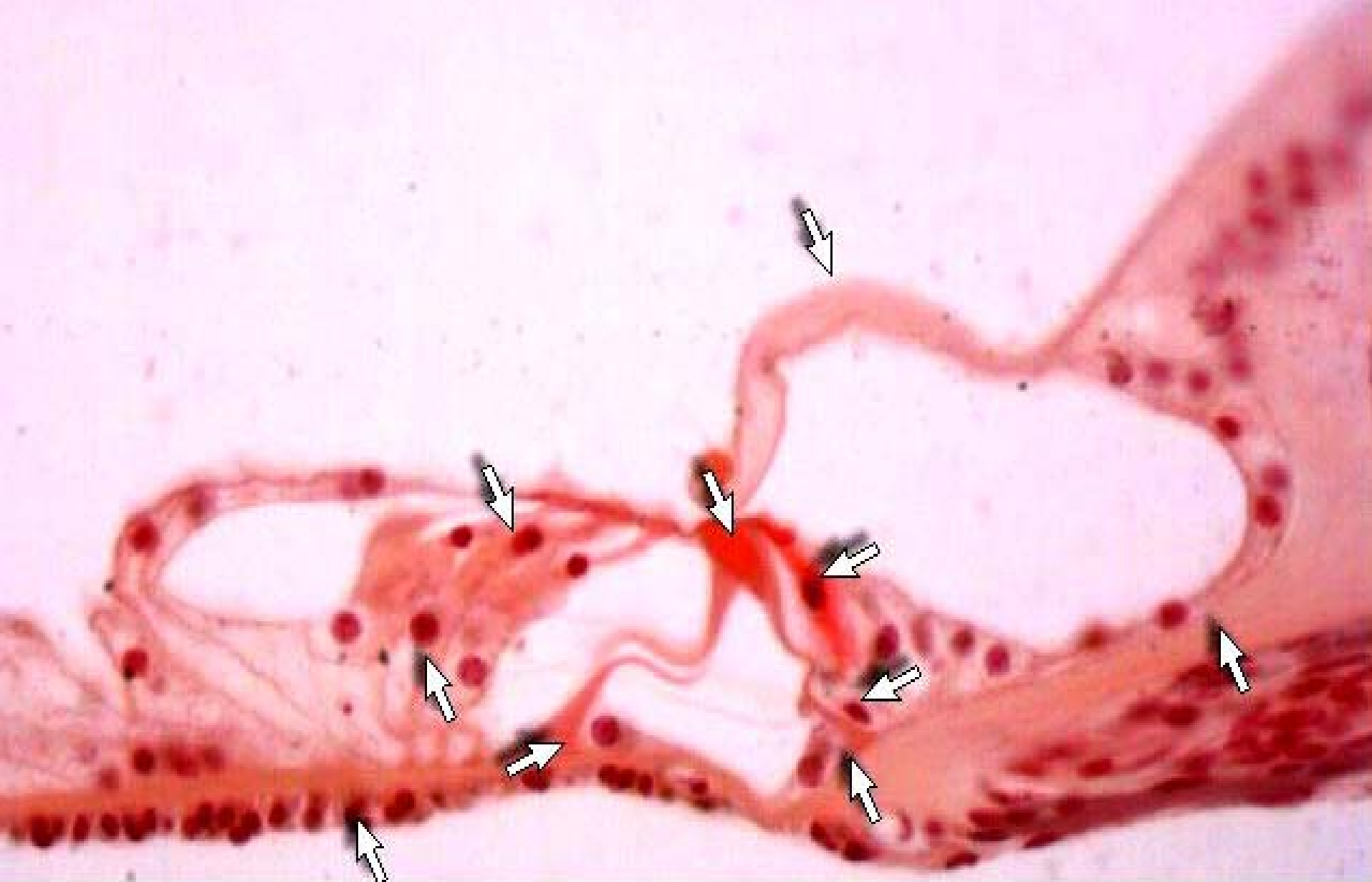Inner ear



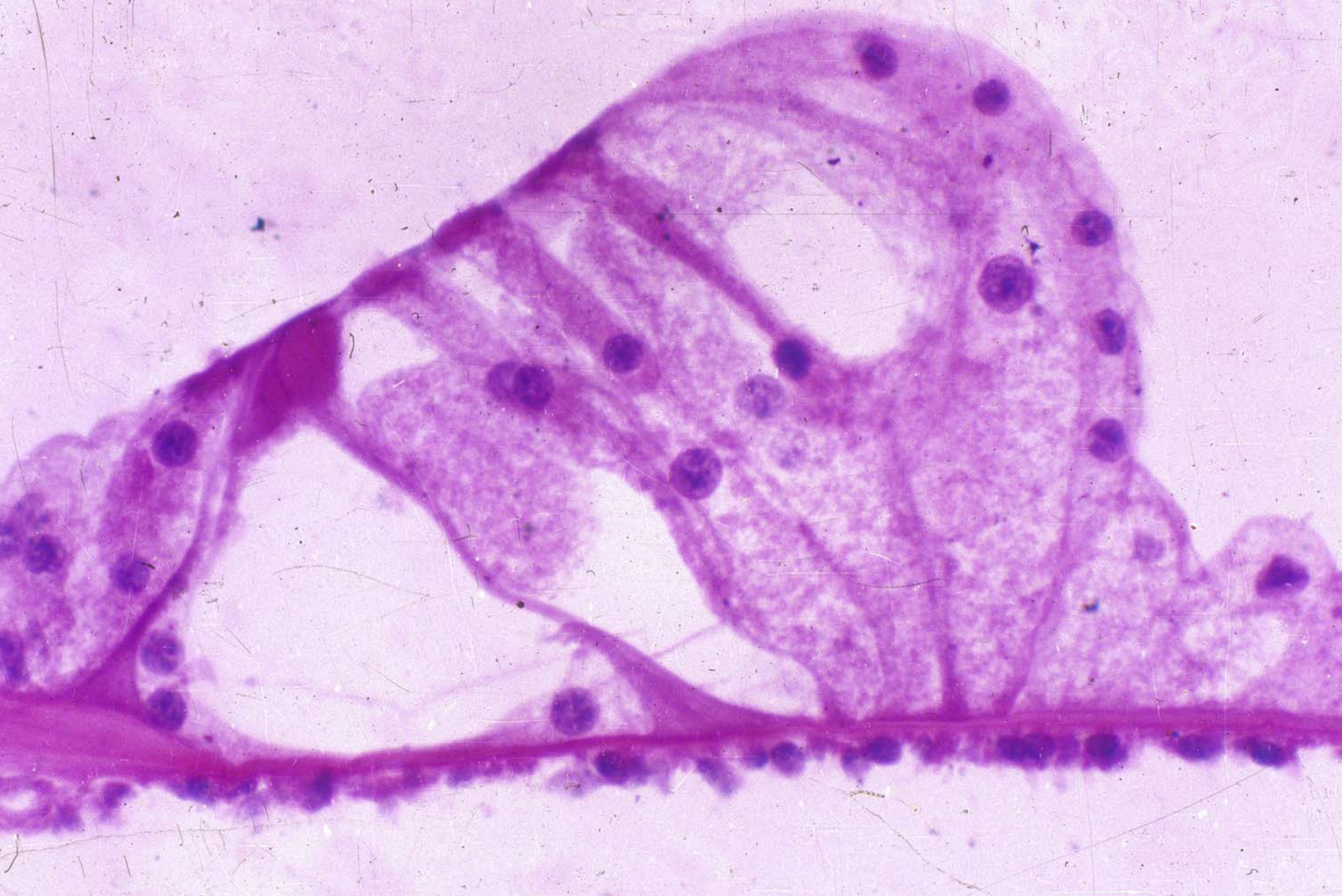Cochlea (scala vestibuli,scala tympani,scala media)




Cochlea (scala vestibuli,scala tympani,scala media)




The spiral organ



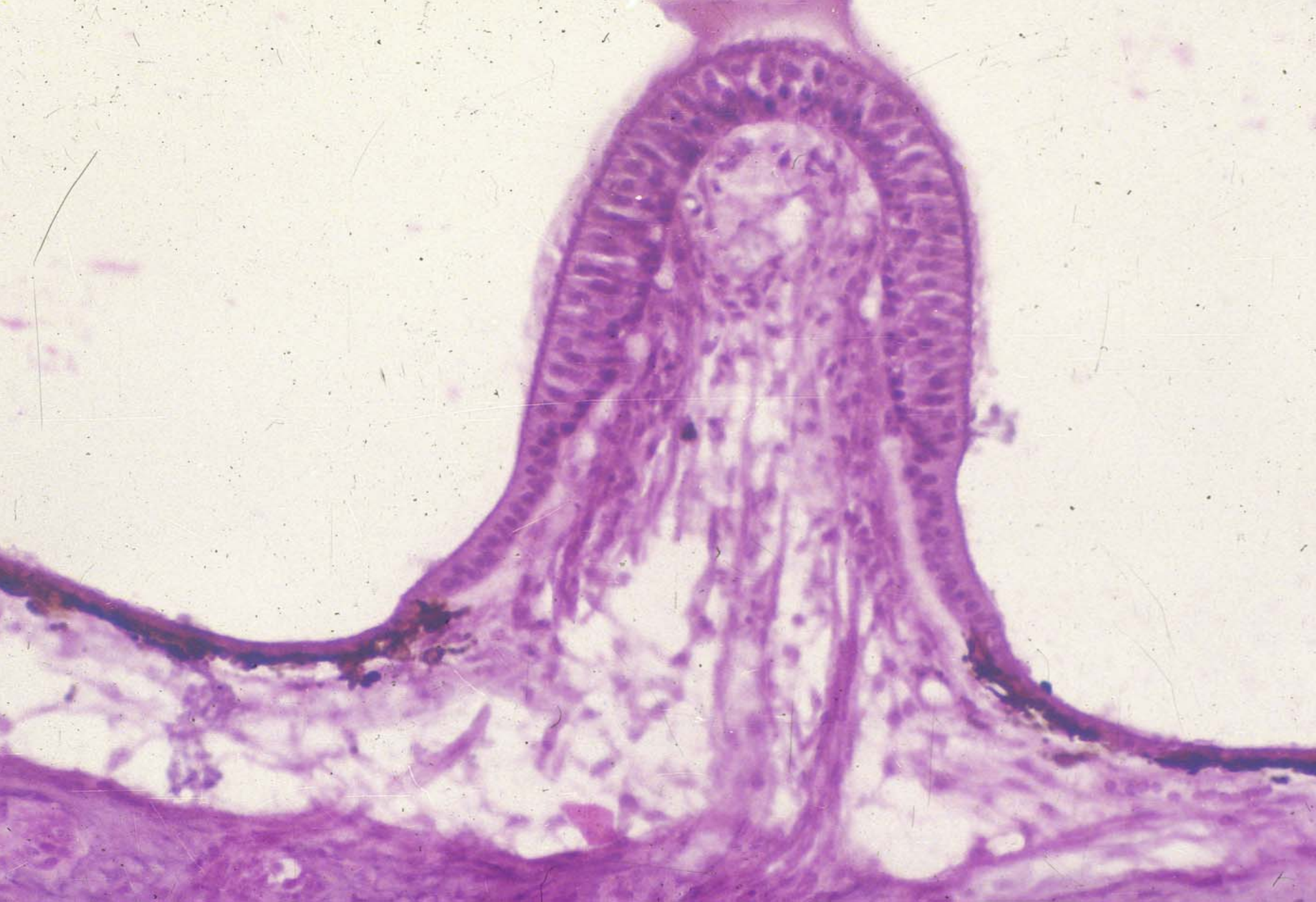
The spiral organ



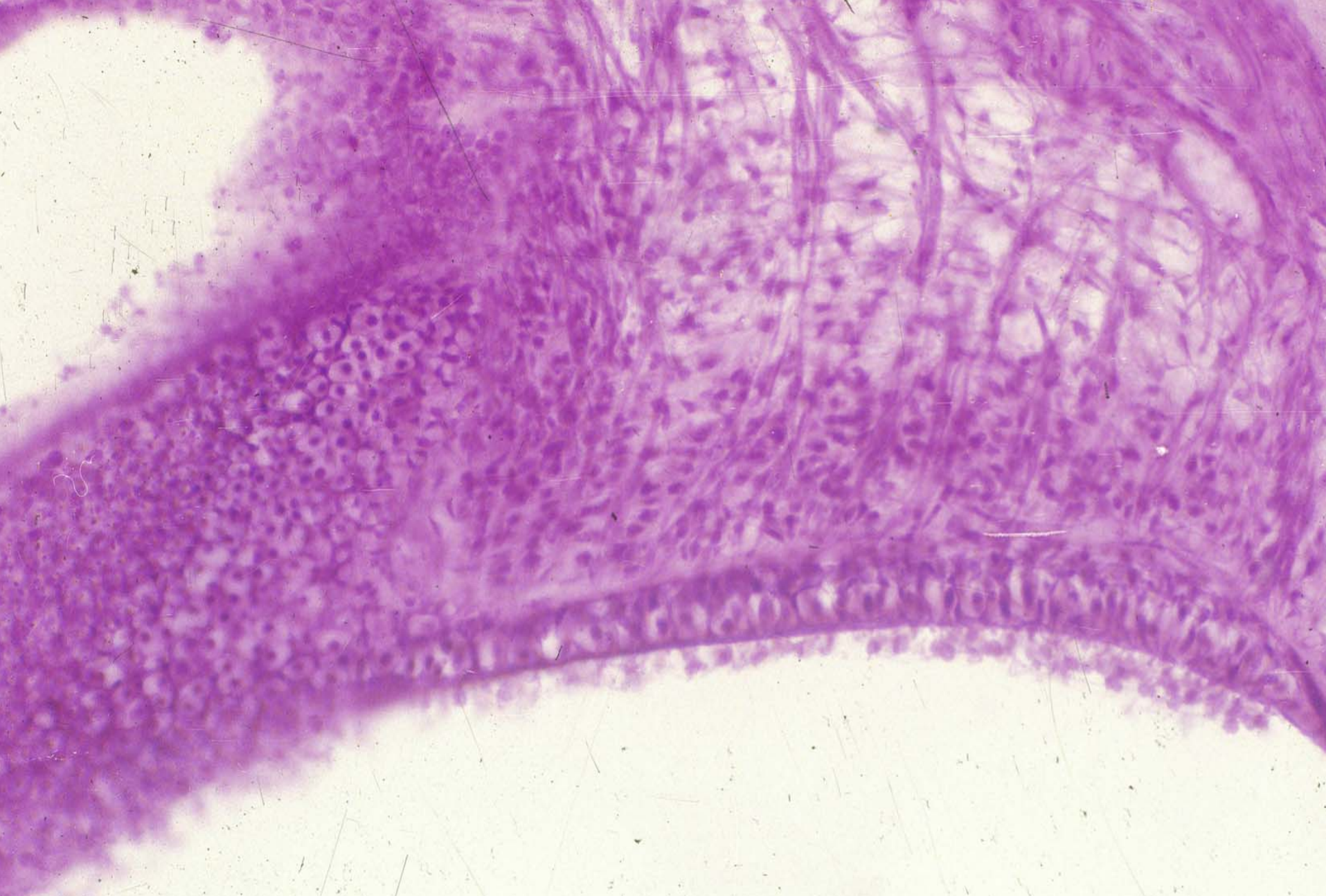
SEM of spiral organ



SEM of spiral organ



Crista ampullaris



Macula acustica

Summary

The structure and function of eyeball.